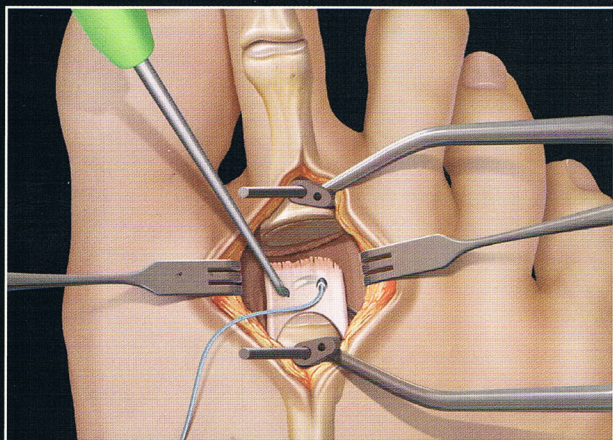


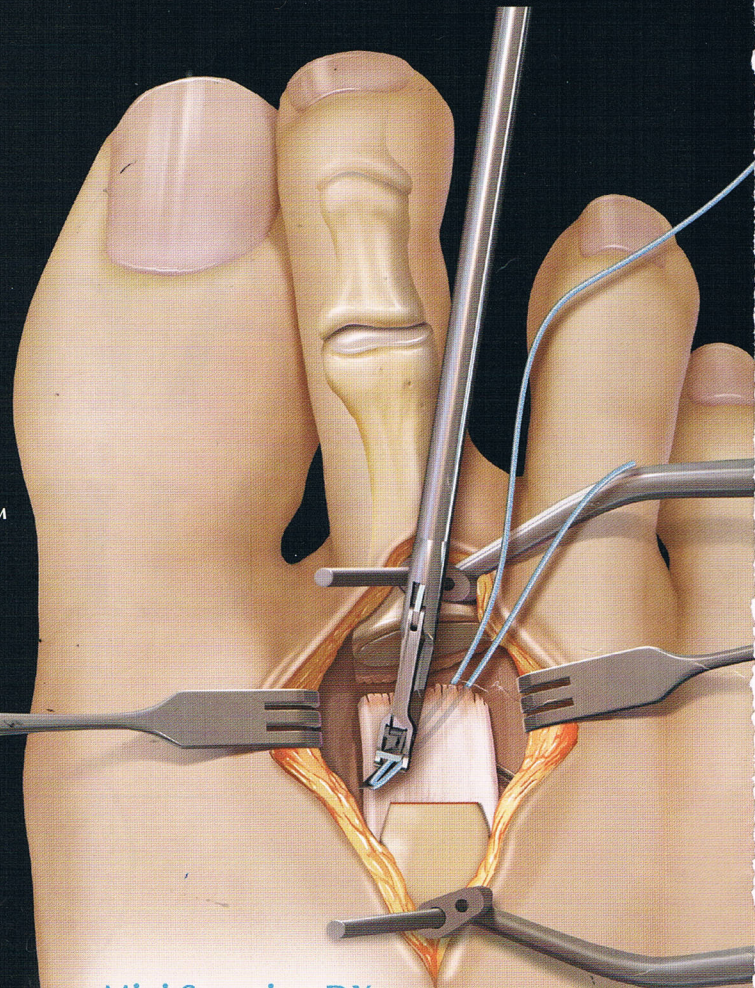
Resuscitate Your MTP Joint Correction!

Complete Plantar Plate Repair (CPR)

- Direct repair from a dorsal incision to treat and prevent crossover and floating toe
- Reconstruct the soft tissue complex to its normal anatomic state, eliminating 2nd MTP joint instability
- The Mini Scorpion™ DX and Micro SutureLasso™ provide state of the art suture passing options for the plantar plate



Micro SutureLasso CPR technique



Mini Scorpion DX
CPR technique


Arthrex innovation, brought to the forefoot

NEW! Mini Scorpion DX

Arthrex

www.Arthrex.com

© 2012, Arthrex Inc. All rights reserved.



Original Research

A Prospective Series of Patients with Chronic Achilles Tendinopathy Treated with Autologous-conditioned Plasma Injections Combined with Exercise and Therapeutic Ultrasonography

Victoria M. Deans, MBChB, MRCS (Eng), MSc¹, Alison Miller, MCSP²,
James Ramos, LMS, MD, PhD, FRCS (GEd), FRCS¹

¹ Department of Trauma and Orthopaedics, Birmingham Heartlands Hospital, Birmingham, United Kingdom

² Department of Physiotherapy, Birmingham Heartlands Hospital, Birmingham, United Kingdom

ARTICLE INFO

Level of Clinical Evidence: 4

Keywords:

Achilles tendon
blood
growth factors
injection
morphogenic protein
physical therapy
platelet-rich plasma
therapeutic ultrasound

ABSTRACT

Chronic Achilles tendinopathy is a difficult problem to manage, because it can result in significant patient morbidity. We conducted a prospective case series involving 26 patients (2 bilateral cases) with painful and ultrasound-confirmed Achilles tendinopathy for a minimum duration of 6 months. Our objective was to assess whether this condition can be effectively treated with a treatment protocol combining an intratendinous autologous-conditioned plasma injection followed by a standardized rehabilitation protocol. The rehabilitation protocol consisted of full weightbearing in a pneumatic cast boot for 6 weeks, therapeutic ultrasound treatment, and an eccentric exercise program. Our results showed statistically significant improvements in terms of pain ($p < .0001$), other symptoms ($p = .0003$), activities of daily living ($p = .0002$), sports activities ($p = .0001$), and quality of life ($p = .0002$). We believe that the use of autologous-conditioned plasma can provide a potential treatment solution for chronic Achilles tendinopathy.

© 2012 by the American College of Foot and Ankle Surgeons. All rights reserved.

The management of chronic Achilles tendinopathy is challenging. It is well established that pain in the Achilles tendon is a common symptom in those who partake in sporting activities (1). However, it is also an increasing problem in less-active individuals (2). Regarding previously used treatment methods for chronic Achilles tendinopathy, the current evidence base has not established which treatment is most effective. Nonsteroidal anti-inflammatory drugs have resulted in poor symptom improvement (3). Laser treatment has given mixed results (4), and Costa et al (5) showed no difference in pain levels between extracorporeal shock wave therapy and dummy treatment in their randomized controlled trial. Occasionally, surgery is used for refractory cases. The objectives of surgery are to excise fibrotic tissue, debride scar tissue that has failed to heal, and suture together the healthy tendon edges. The results have varied, with 1 series reporting

67% of patients having physical activity restored at 7 months of follow-up but a 19% complication rate (6).

The tendinopathy stems from the poor vascularity of the tendons, which results in their limited capacity for healing (7,8). In the Achilles tendon, evidence supports the theory that there is a relative hypovascular region 2 to 6 cm from its calcaneal insertion (8). This hypovascularity can be worsened by exercise (9). The pain mechanisms associated with chronic tendinopathies are poorly understood, but it is believed they are secondary to neurovascular ingrowth that occurs in tendon healing rather than being inflammatory in nature (10).

Autologous-conditioned plasma (ACP) is a platelet- and growth factor-rich solution that stimulates angiogenesis and the healing process (11,12). The use of ACP was approved by the National Institutes of Clinical Excellence in their May 2008 report (13). A paucity of randomized clinical trials of ACP use have been published, with most studies being laboratory, animal, or small patient pilot studies. The ACP system is used to generate platelet-rich plasma (PRP); thus, the 2 terms can be used interchangeably.

The mechanism of action of ACP works because, outside the bloodstream, platelets are activated to release proliferative and morphogenic proteins. These growth factors stimulate healing in a variety of tissues, including bone, tendon, cartilage, and skin (14). The main actions seem to involve the synergistic effects of growth factors (15–17) and include induction of proliferation and

Financial Disclosure: Arthrex, Inc. (Naples, FL) supplied the centrifuge used in our investigation. None of the authors received any payment or support in any other direct or indirect way from Arthrex, Inc., and no one from Arthrex, Inc., participated in the design or execution of the study protocol.

Conflicts of Interest: None reported.

Address correspondence to: Victoria M. Deans, MBChB, MRCS (Eng), MSc, Department of Trauma and Orthopaedics, Birmingham Heartlands Hospital, Birmingham B9 5SS United Kingdom.

E-mail address: vdeans@doctors.org.uk (V.M. Deans).

Table
Summary of probabilities of null hypothesis (*p* values) for results of Foot and Ankle Outcome Score* (n = 28 Achilles tendons in 26 patients)

FAOS Category	SD	Baseline Pre- and Post-Treatment†
Pain	21.91 ± 22.75	41.13 ± 64.32
Symptoms	22.04 ± 18.62	53.30 ± 71.70
Activities of daily living	21.35 ± 20.64	55.10 ± 74.82
Sport/recreation	35.48 ± 29.25	42.58 ± 80.35
Quality of life	18.03 ± 25.26	16.89 ± 36.62

Abbreviations: FAOS, Foot and Ankle Outcome Score; SD, standard deviation.

* Data excluded 1 patient with Achilles tendon rupture.

† Duration of follow-up was 6 weeks.

28 to 64) years. All the patients who received injections in our study had been experiencing symptoms for longer than 6 months, with the symptoms refractory to various other nonoperative treatments. After the initial consultation, each patient underwent an ultrasound scan by a single musculoskeletal specialist consultant radiologist (D.T.). The ultrasound changes included echo alteration and tendon swelling (Fig. 1). Of the 26 patients, 24 (92.31%) received 1 injection of ACP into their affected tendon, with the remaining 2 patients given a second injection 6 weeks later. These 2 patients were given a second injection because subjectively and objectively they still had significant symptoms at their 6-week follow-up visit. The 2 patients who received a second injection also completed 2 FAOS questionnaires with the same timing, 1 before treatment and 1 at 6 weeks.

We found a statistically significant improvement in the outcomes of our patients in all categories of the FAOS questionnaire, including pain, other symptoms, activities of daily living, sports/recreation, and QOL. The probabilities of the null hypothesis (*p* values) for the differences between the pre- and post-treatment outcomes are summarized in Table. The results from the 5 FAOS categories are graphically represented in Figs. 2 through 6; 0 was the worst score, indicating severe pain/symptoms and reduced QOL/activity, and 100 as the highest score, indicating no pain/symptoms and normal QOL/activity. The results revealed that with regard to pain, in particular, marked subjective improvement occurred after injection. In our series, 23 (88%) of 26 patients had a decrease in pain, 2 (8%) reported no change, and 1 (4%) had worse pain after the injection and treatment at 6 weeks of clinical follow-up.

Regarding the other symptoms, 21 (81%) of the 26 patients reported improved symptoms at the follow-up point, with 5 (19%) having slightly worse symptoms. Of those with worse symptoms, their FAOS score was, on average, 9% worse. Of those with improvement, the mean improvement in the score at 6 weeks of clinical follow-up was 30% (range -12% to +82%).

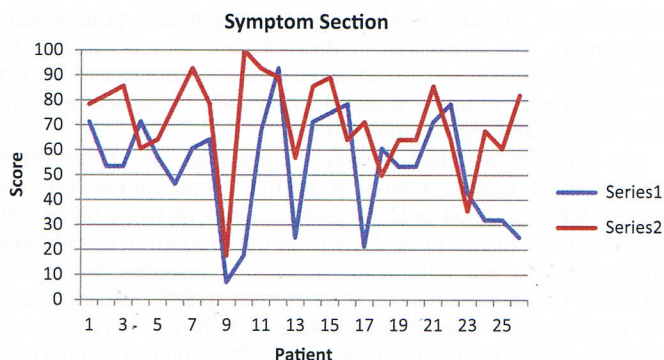


Fig. 3. Graphs showing results of Foot and Ankle Outcome Score for symptoms. Series 1, before injection/treatment; series 2, postinjection treatment at 6 weeks of follow-up.

For activities of daily living, 2 (8%) of 26 reported they were marginally worse at the 6-week follow-up point, a mean of 13% (range 0% to 13%) worse. However, 4 (15%) of 26 patients reported no change, and 20 (77%) reported an improvement at the 6-week follow-up visit. The mean improvement was 30% (range -14% to +72%). Similar results were found for sports and recreational activities, with 2 (8%) reporting being marginally worse, 5 (19%) the same, and 19 (73%) improvement at the 6-week follow-up visit. Most of our patients did not partake in any sporting activities, which might account for the proportion that reported no change from before the intervention. Although 20 (77%) of the 26 patients reported an improved QOL at the 6-week review, the scores had improved less than they had for the pain and other symptoms categories. Nonetheless, all the outcome improvements were statistically significant, suggesting that the changes were likely from injection of the ACP and the exercise regimen and were not simply chance observations.

During our study, we had 1 complication (3.85%), involving rupture of the involved Achilles tendon 41 days after injection. This patient was male, and he had removed his cast boot prematurely at 4 weeks against our advice and was gardening at the time of the rupture. This patient had had a very degenerate tendon on ultrasound before injection, and it was impossible to precisely know whether the ACP injection contributed to the rupture or if it was solely due to the degenerative pathologic features already present and the excessive mechanical load. The same patient later experienced a rupture of the contralateral Achilles tendon, which had not received any formal diagnosis or treatment. He was excluded from the results because his treatment changed when he underwent surgery to repair his ruptured Achilles tendon. An additional patient (3.85%) did not comply with

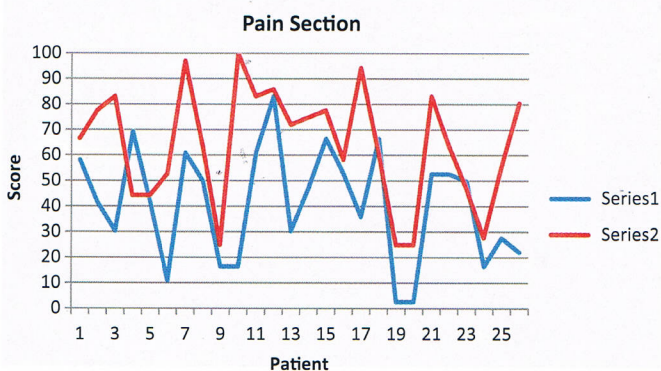


Fig. 2. Graphs showing results of Foot and Ankle Outcome Score for pain. Series 1, before injection/treatment; series 2, postinjection treatment at 6 weeks of follow-up.

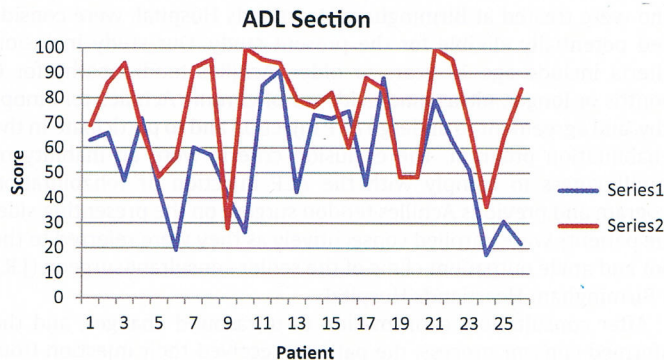


Fig. 4. Graphs showing results of Foot and Ankle Outcome Score for activities of daily living (ADL). Series 1, before injection/treatment; series 2, postinjection treatment at 6 weeks of follow-up.

differentiation of cells, production of collagen and proteoglycan, angiogenesis, and chemotaxis. Macrophages, mesenchymal stem cells, and osteoblasts are also attracted by these proteins and, once at the healing site, promote removal of necrotic tissue and enhance tissue healing and regeneration (3).

ACP provides platelets at a supraphysiologic concentration to enhance these healing effects. A normal blood sample typically contains 93% red blood cells, 6% platelets, and 1% white blood cells (18). ACP alters this ratio by decreasing the proportion of red blood cells, which are less helpful in the healing response, to 5%, and increasing the more beneficial platelet ratio to 94% (18). Lyras et al (19) injected the Achilles tendons of 48 skeletally mature rabbits with PRP after transverse tendon transection. They found the injections significantly enhanced neovascularization in this group compared with that in the control group early in the first 2 weeks after injection.

In a nonrandomized controlled trial of 20 patients with chronic elbow tendinosis, Mishra and Pavelko (20) injected 15 patients with PRP and 5 control patients with a local anesthetic. The pain scores in these patients had decreased by 93% ($p < .001$) at the final 26-month follow-up examination in the PRP group. Barrett et al (21) conducted a pilot study that involved injecting 9 patients with ultrasound-confirmed plantar fasciitis with PRP. They had positive results with 6 patients (66.7%), who experienced complete symptom relief at 2 months and 1 (11.1%) additional patient after a second injection.

One of the few randomized controlled trials that focused on PRP injections, by de Vos et al (22), treated 54 randomized patients with chronic Achilles tendinopathy. They all received an eccentric exercise program combined with either a PRP injection ($n = 27$) or saline injection ($n = 27$). They found that both groups improved significantly at 24 weeks, but no significant difference was found between the outcomes of the 2 groups in pain and activity levels (22). A review of the effects of PRP injection by Sampson et al (23) concluded that no studies had reviewed the results of post-PRP injection rehabilitation. They also noted that no specific post-PRP physical therapy protocols were available that were focused on the rehabilitation of the Achilles tendon.

In an effort to further clarify the role of ACP injection combined with a standardized rehabilitation program for the treatment of chronic Achilles tendinopathy in humans, with an emphasis on pain reduction and improved function, we undertook a prospective study of a series of such patients. We hypothesized that such treatment would significantly reduce the pain associated with Achilles tendinopathy.

Patients and Methods

From October 2009 to March 2012, consecutive patients with ultrasound-confirmed chronic Achilles tendinopathy (2 bilateral), who were treated at Birmingham Heartlands Hospital, were considered potentially eligible for the present study. Our study inclusion criteria include age 18 years or older, Achilles tendinopathy for 6 months or longer, ultrasound evidence of chronic Achilles tendinopathy, and agreement to undergo ACP injection and to participate in the rehabilitation program. The exclusion criteria were an inability or unwillingness to comply with the ACP injection or rehabilitation program and previous Achilles tendon surgery on the presenting side. The patients were enrolled consecutively as they were referred to the foot and ankle outpatient clinic of the senior consultant surgeon (J.R.) at Birmingham Heartlands Hospital.

After consultation, confirmation of ultrasound changes, and the informed consent process, the patients received their injection from a single registrar orthopedic surgeon (V.M.D.) using a standardized technique. Initially, an aseptic 10-mL venous blood sample was taken from the patients using the Arthrex (Arthrex, Naples, FL) double

syringe. This was centrifuged at 1500 revolutions/min for 5 minutes and removed from the Arthrex ACP Autologous Conditioned Plasma, Double Syringe System (Arthrex). Next, 3 mL of the separated conditioned plasma (ACP, PRP) was aspirated into a second 5-mL syringe. The remaining cellular content was discarded. The 3 mL of ACP was aseptically injected using a 21-gauge needle into the affected tendon without the use of local or general anesthetic at the points of maximal tenderness identified by the patient. The injection site was also correlated with the area of worst pathologic findings on the ultrasound scan but was not performed under ultrasound guidance. The needle was identified as being intratendinous by the increase in resistance as the needle entered the tendon substance.

All patients received a standardized 6-week rehabilitation program administered by our senior physiotherapist (A.M.). Each patient wore a pneumatic cast boot for 6 weeks after injection and was fully weightbearing. The patients initially had 2 weeks rest in the pneumatic boot after injection in an effort to allow the tissues to respond to the induction of the growth factors. Therapeutic ultrasound was begun from week 2 and was repeated at weeks 3 to 6 after injection of ACP. From 2 weeks onward, each patient was also given an eccentric exercise program. Achilles tendon exercises were initiated in a non-weightbearing fashion and progressed to weightbearing as tolerated and were supervised weekly. The patients were taught to remove the boot 5 times daily to perform their eccentric exercises.

Our primary outcome was that of pain reduction, and our secondary outcomes of interest included changes in other symptoms, activities of daily living, sports activities, and quality of life (QOL). The participants completed the Foot and Ankle Outcome Score (FAOS) questionnaire (24) before and after the treatment regimen, and the results were compared. Our patients completed 1 FAOS questionnaire (24) before their injection and a second FAOS questionnaire 6 weeks later at follow-up. The FAOS scores the 5 categories of pain, symptoms, activities of daily living, sports/recreation, and QOL.

We conducted Wilcoxon matched pairs signed rank test on our 2 FAOS results. The Wilcoxon test was selected for the data because the data were nonparametric and dependent. Statistical significance was defined at the 5% ($p \leq .05$) level.

Results

A total of 26 patients (2 bilateral) were enrolled in the investigation, for a total of 28 Achilles tendons. Ten patients (38.46%) were male and 16 (61.54%) were female, with an overall mean age of 45.77 (range

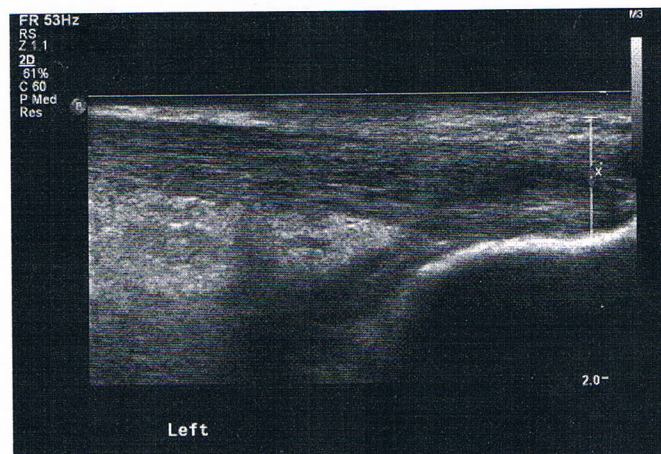


Fig. 1. Ultrasound scan showing chronic Achilles tendinopathy with hyperechoic changes indicative of edema within the tendon substance.

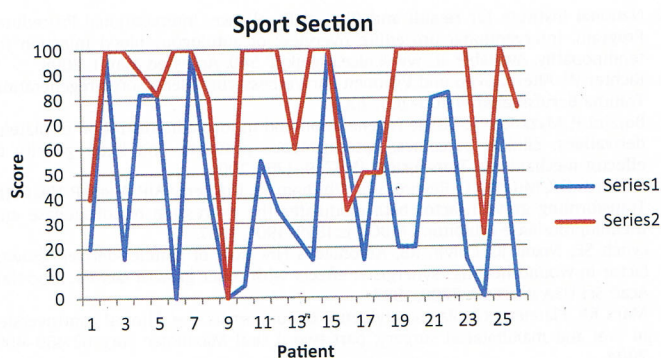


Fig. 5. Graphs showing results of Foot and Ankle Outcome Score for sport/recreation. Series 1, before injection/treatment; series 2, postinjection treatment at 6 weeks of follow-up.

wearing the pneumatic boot or doing the rehabilitation exercise regimen but was included in the analysis.

Three patients (11.54%) had significant comorbidities, including gynecologic, cardiac, and diabetic diagnoses. Two patients (7.69%) had difficulties at work. One (3.85%) was receiving pressure to return to work before completing the 6-week course of rehabilitation exercises, and another (3.85%) with an ongoing work-related disability claim outstanding. We acknowledge that this could potentially have meant that their FAOS scores were affected because they could have reported lower scores after treatment owing to their comorbidities and work issues acting as confounding variables. However, this, if anything, would have made our overall results seem worse rather than better.

Discussion

The chronic painful Achilles tendon is a common presentation in general and podiatric practices and orthopedic/sports medicine clinics. Although animal and early studies of ACP injections have shown promising results, very few have combined this with a structured rehabilitation protocol to try and improve the outcomes.

We used the FAOS because it specifically aims to assess patients' opinions of their foot and ankle problems. It is a user-friendly document that provided numeric outcome scores. We demonstrated a significant improvement in all 5 categories in our patients after the injection and rehabilitation program, particularly with regard to the pain scores, supporting our original hypothesis. The results of our investigation were similar to previous studies of PRP injections, which have frequently shown an improvement with regard to pain. Three case series evaluated pain after PRP injections using the Nirschl score (25), which scores pain from 0 to 7 (0, no pain and 7, constant pain at rest/disrupts sleep). The results showed a significant improvement in pain in 35 patients with refractory lateral epicondylitis from 6 points at baseline to 0 points at 6 months of follow-up ($p < .001$) (25), in 28 patients with refractory lateral epicondylitis from 6.5 points at baseline to 2.0 points at 9.5 months of follow-up (26), and 20 patients with refractory medial epicondylitis from 6.0 at baseline to 1.0 at 6 months of follow-up ($p < .001$) (27).

Our patients did not experience as great an improvement in the QOL FAOS score as they did in regard to the pain or other outcome categories. This might have been because, although most subjects experienced less pain, they had not reached a "normal" score of 100 and thus were not entirely pain and symptom free. This was reflected in the QOL section, because they had not been able to fully resume the activity levels they enjoyed before their injury. This score could also have been lower secondary to the other comorbidities

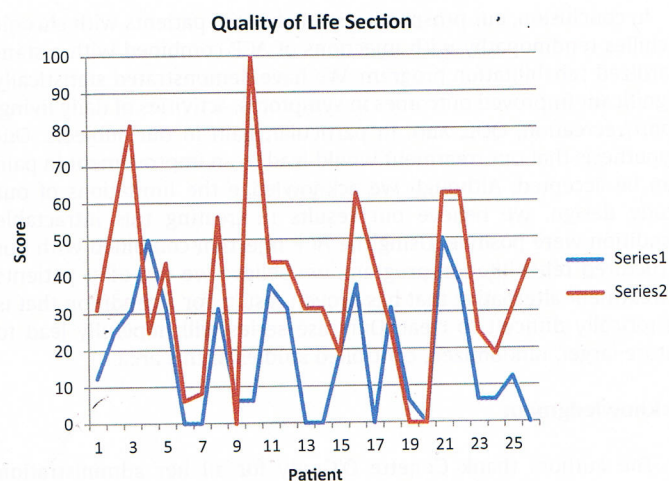


Fig. 6. Graphs showing results of Foot and Ankle Outcome Score for quality of life. Series 1, before injection/treatment; series 2, postinjection treatment at 6 weeks of follow-up.

present in some of our patients, because improvement in their "heel pain" might not have improved their overall QOL owing to symptoms from other conditions.

Although eccentric exercise training is not a new concept, several trials showing positive results have renewed interest in their use (28–30). Roos et al (29) found in their randomized controlled trial that eccentric exercises reduced pain and improved function in patients with chronic Achilles tendinopathy. The Alfredson protocol (28) produced an 82% patient satisfaction level after treating patients with chronic Achilles tendinopathy with eccentric exercises for 12 weeks, results superior to the control group performing concentric exercises in their study. This understanding served as the evidence base for our choice of a 6-week eccentric exercise schedule for the first component of our rehabilitation program. The second aspect of our program entailed the use of therapeutic ultrasound. Therapeutic ultrasound is a popular physical treatment for tendon disorders, although published evidence is scarce for its influence on tendon healing involving human subjects. The benefits shown in a number of animal studies included increased tensile strength, tendon mobility, and energy absorption, improved collagen fibril alignment, and a reduction in inflammatory infiltrate (31,32). It has been hypothesized that the healing benefits of ultrasound resulting from its thermal effects on tissues could include increased blood flow and extensibility of collagen fibers and also a pro-inflammatory response (33). Whether these same effects occur in human tendons is not clearly known.

Our study had several limitations that threaten the validity of our conclusions. We recognize that the sample size was small and that no control group or randomization was used. Also, 1 patient was excluded from the 6-week results. Despite these biases, we believe that exclusion of the patient biased our results toward a null effect and that we still observed statistically significant changes in the outcomes of interest. We acknowledge that because our study was a case series with more than 1 treatment (ACP injection, brace immobilization and protected weightbearing, therapeutic ultrasound, and exercise) used simultaneously, it was not possible to determine how much of each treatment contributed to the improved results. Furthermore, the FAOS was not tested for validity and reliability for our specific patient population; thus, we cannot report that it is a valid and reliable scoring system for this population. Finally, our treatment regimen requires patients to receive the ACP injection, wear the cast boot, participate in the rehabilitation program, and be off from work for 6 weeks, which might not be practical or possible for some patients.

In conclusion, our prospective study treated patients with chronic Achilles tendinopathy with injections of ACP combined with a standardized rehabilitation program. We have demonstrated statistically significant improved outcomes in symptoms, activities of daily living, sport/recreation, QOL, and, in particular, pain in our subjects. Our hypothesis that our treatment would lead to an improvement in pain can be accepted. Although we acknowledge the limitations of our study design, we believe our results in treating this intractable condition were positive. Using the ACP injection combined with our structured rehabilitation program, we believe we can offer patients a treatment alternative that has proven results for a condition that is historically difficult to treat. Our case series will hopefully lead to future larger, randomized, controlled studies in this area.

Acknowledgment

The authors thank Genette O'Grady for all her administration organizing, Dave Wood (Arthrex) who reliably brought the centrifuge kit, and Dr. David Tudway, consultant radiologist, for performing and reporting the ultrasound scans.

References

- Maffulli N, Khan KM, Puddu G. Overuse tendon conditions: time to change a confusing terminology. *Arthroscopy* 14:840–843, 1998.
- Alfredson H, Lorentzon R. Chronic Achilles tendinosis: recommendations for treatment and prevention. *Sports Med* 29:135–146, 2000.
- Astrom M, Westlin N. No effect of piroxicam on Achilles tendinopathy: a randomized study of 70 patients. *Acta Orthop Scand* 63:631–634, 1992.
- Basford JR. Low intensity laser therapy: still not an established clinical tool. *Lasers Surg Med* 16:331–342, 1995.
- Costa ML, Shepstone L, Donell ST, Thomas TL. Shock wave therapy for chronic Achilles tendon pain: a randomized placebo-controlled trial. *Clin Orthop Relat Res* 440:199–204, 2005.
- Paavola M, Kannus P, Orava S, Pasanen M, Jarvinen M. Surgical treatment for chronic Achilles tendinopathy: a prospective seven month follow up study. *Br J Sports Med* 36:178–182, 2002.
- Ahmed IM, Lagopoulos M, McConnell P, Soames RW, Sefton GK. Blood supply of the Achilles tendon. *J Orthop Res* 16:591–596, 1998.
- Carr AJ, Norris SH. The blood supply of the calcaneal tendon. *J Bone Joint Surg Br* 71:100–101, 1989.
- Langberg H, Bulow J, Kjaer M. Blood in the peritendinous space of the human Achilles tendon during exercise. *Acta Physiol Scand* 163:149–153, 1998.
- Alfredson H, Cook J. A treatment algorithm for managing Achilles tendinopathy: new treatment options. *Br J Sports Med* 41:211–216, 2007.
- Anitua M, Sanchez E, Nurden A, Nurden P, Orive G, Andia I. New insights into and novel applications for platelet-rich fibrin therapies. *Trends Biotechnol* 24:227–234, 2006.
- Everts P, Knappe J, Weirich G, Schonberger J, Hoffman J, Overdeest E, Box H, van Zundert A. Platelet-rich plasma and platelet gel: a review. *JECT* 38:174–187, 2006.
- National Institute for Health and Clinical Excellence. Interventional Procedures Program. Interventional procedure overview of autologous blood injection for tendinopathy. Available at: www.nice.org.uk/IP_549. Accessed May 1, 2008.
- Richter W. Alternativen und Visionen zur Verbesserung der Knorpelregeneration. *Trauma Berufskrankh* 4:100–103, 2002.
- Borzini P, Mazzucco L. Tissue regeneration and in loco administration of platelet derivatives: clinical outcomes, heterogeneous products, and heterogeneity of effector mechanisms. *Transfusion* 45:1759–1767, 2005.
- Edwards DR, Murphy G, Reynolds JJ, Whitham SE, Docherty AJP, Angel P, Heath JK. Transforming growth factor beta modulates the expression of collagenase and metalloproteinase inhibitor. *EMBO J* 6:1899–1904, 1987.
- Lynch SE, Nixon JC, Colvin RB, Antoniadis HN. Role of platelet-derived growth factor in wound healing: synergistic effects with other growth factors. *Proc Natl Acad Sci USA* 84:7696–7700, 1987.
- Marx RE. Platelet-rich plasma: evidence to support its use. Clinical controversies in oral and maxillofacial surgery, part two. *J Oral Maxillofac Surg* 62:489–496, 2004.
- Lyras DN, Kazakos K, Verettas D, Polychronidis A, Tryfonidis M, Botaitis S, Agrogiannis G, Simopoulos C, Kokka A, Patsouris E. The influence of platelet-rich plasma on angiogenesis during the early phase of tendon healing. *Foot Ankle Int* 30:1101–1106, 2009.
- Mishra A, Pavelko T. Treatment of chronic elbow tendinosis with buffered platelet-rich plasma. *Am J Sports Med* 10:1–5, 2006.
- Barrett S, Erredge S. Growth factors for chronic planter fasciitis. *Podiatry Today* 17:37–42, 2004.
- De Vos RJ, Weir A, van Schie HTM, Bierma-Zeinstra SMA, Verhaar J, Weinans H, Tol JL. Platelet-rich plasma injections for chronic Achilles tendinopathy. *JAMA* 303:144–149, 2010.
- Sampson S, Gerhardt M, Mandelbaum B. Platelet rich plasma injection grafts for musculoskeletal injuries: a review. *Curr Rev Musculoskelet Med* 1:165–174, 2008.
- Foot and Ankle Outcome Score (FAOS), English version LK 1.0. Available at: www.koos.nu. Accessed July 10, 2012.
- Connell DA, Ali KE, Ahmad M, Lambert S, Corbett S, Curtis M. Ultrasound-guided autologous blood injection for tennis elbow. *Skeletal Radiol* 35:371–377, 2006.
- Edwards SG, Calandruccio JH. Autologous blood injections for refractory lateral epicondylitis. *J Hand Surg* 28:272–278, 2003.
- Suresh SPS, Ali KE, Jones H, Connell DA. Medial epicondylitis: is ultrasound guided autologous blood injection an effective treatment? *Br J Sports Med* 40:935–939, 2006.
- Alfredson H, Pietila T, Jonsson P, Lorentzon R. Heavy-load eccentric calf muscle training for the treatment of chronic Achilles tendinosis. *Am J Sports Med* 26:360–366, 1998.
- Roos EM, Engstrom M, Lagerquist A, Soderberg B. Clinical improvement after 6 weeks of eccentric exercise in patients with mid-portion Achilles tendinopathy—a randomized trial with 1-year follow up. *Scand J Med Sci Sports* 14:286–295, 2004.
- Mafi N, Lorentzon R, Alfredson H. Superior short-term results with eccentric calf muscle training compared to concentric training in a randomized prospective multicenter study on patients with chronic Achilles tendinosis. *Knee Surg Sports Traumatol Arthrosc* 9:42–47, 2001.
- Enwemeka CS. The effects of therapeutic ultrasound treatment on tendon healing: a biomechanical study. *Am J Phys Med Rehabil* 68:283–287, 1989.
- Gans BS, Huys S, Sherebrin MH, Scilley CG. The effects of ultrasound treatment on flexor tendon healing in the chicken limb. *J Hand Surg Br* 20:809–814, 1995.
- Speed CA. Therapeutic ultrasound in soft tissue lesions: review. *Rheumatology* 40:1331–1336, 2001.